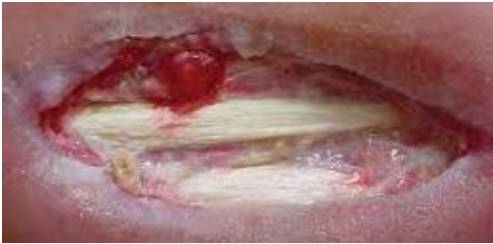

COMMON WOUND TERMINOLOGY

EPIBOLE:

When the epidermis grows over the wound edges and creates curved edges into the wound



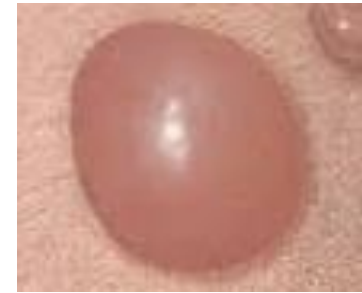EPITHELIAL TISSUE:

Pink tissue that grows over the wound toward the end of the healing process; Closes the wound



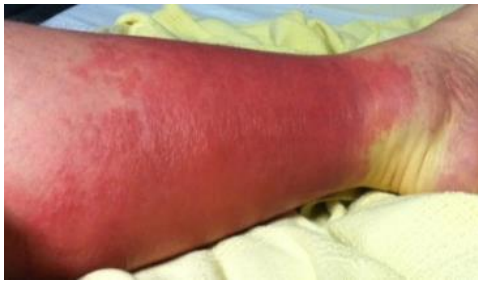BULLA:

Clear fluid filled blisters > 1 cm



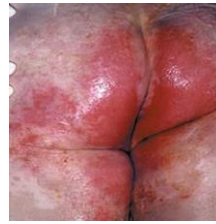CELLULITIS:

Bacterial skin infection; Area is usually red, warm, and swollen



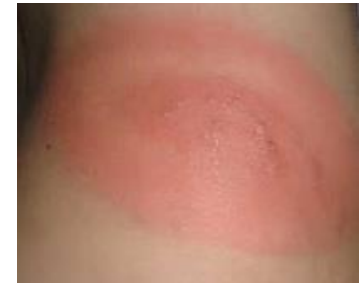DENUDED/ EXCORIATION/ EROSION/ MACERATION:

Epidermis is removed from exposure to moisture such as urine, feces, drainage, and other body fluids. Skin appears white and sometimes wrinkly



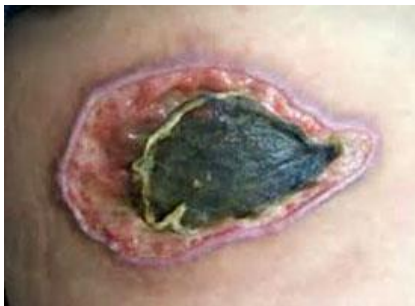ERYTHEMA:

Redness



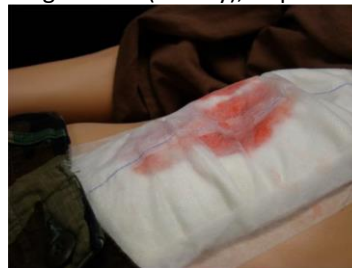ESCHAR:

Dry, firm, leathery necrotic tissue



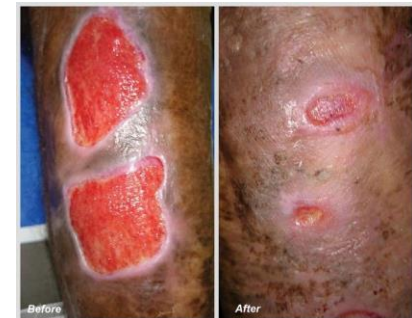EXUDATE:

Drainage coming from the wound. Can be scant, minimal, moderate, or large/copious amounts; can be serous (clear), serosanguinous (mix of clear and bloody fluid), sanguineous (bloody), or purulent (pus)



CONTRACTION:

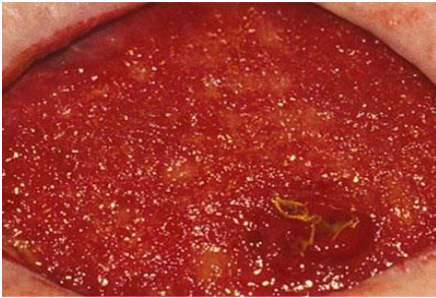
When the wound becomes smaller during the proliferation phase of the wound healing process



COMMON WOUND TERMINOLOGY

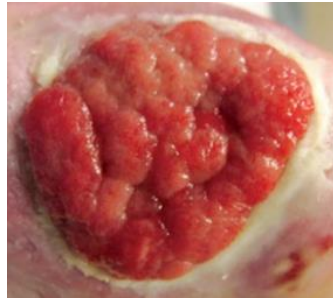
GRANULATION:

Only seen in full thickness wounds. Beefy red bumpy connective tissue and blood vessels



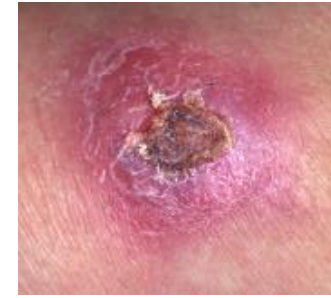HYPERGRANULATION:

When granulation tissues build up above the level of the epidermis



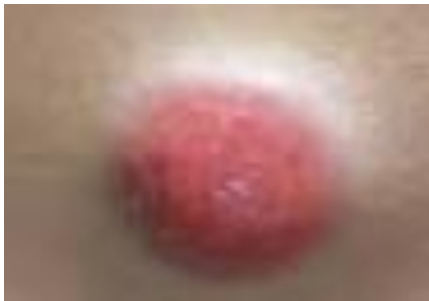INDURATED:

Peri wound skin that has become hard/tough



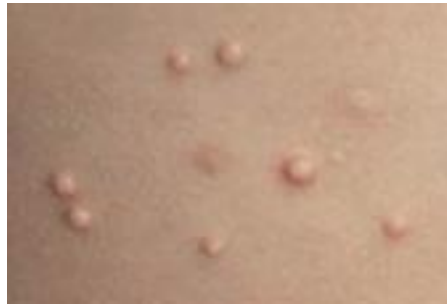NODULE:

Circular lesion > 1cm not clear fluid filled



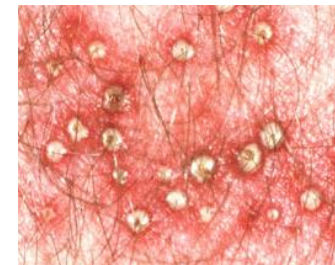
PAPULE:

A lesion < 1cm superficial and solid



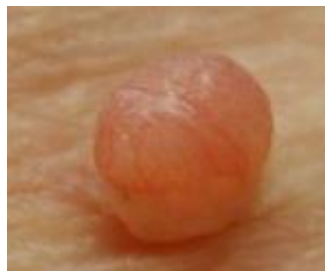PUSTULE:

Circular lesion varies in size fluid filled with Leukocytes (pus)



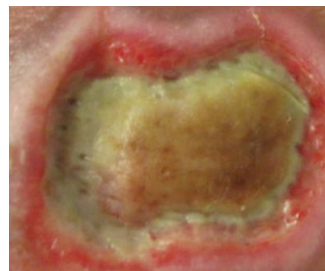
SKIN TAG:

Benign skin growth- looks like a small soft balloon of hanging skin



SLOUGH:

Moist necrotic tissue. Can be yellow, gray, tan, or brown. Thin and fibrous stringy or mucinous



VESICLE:

<1cm circular clear fluid filled blister

